

# Effect of Co-Administration of Aqueous Extract of *Hibiscus Sabdariffa* Linn (*Malvaceae*) Calyx and Vitamin E on Carbamazepine-Induced Testicular Changes in Adult Wistar Rats

I. Suleiman<sup>1</sup>, M. U. Kawu<sup>2</sup>, Y. Tanko<sup>3</sup>, M. Shitu<sup>4</sup>

<sup>1,3</sup> Department of Human Physiology, Faculty of Medicine, Ahmadu Bello University, Zaria, Kaduna, Nigeria.

<sup>2</sup> Department of Veterinary Physiology and Pharmacology, Faculty of Veterinary Medicine, Ahmadu Bello University, Zaria, Kaduna State, Nigeria.

<sup>4</sup> Department of Veterinary Pharmacology and Toxicology, Faculty of Veterinary Medicine, Ahmadu Bello University, Zaria, Kaduna State, Nigeria.

---

**Abstract:** The antioxidant potential of many flavonoid containing plants is increasingly being exploited in therapy. *Hibiscus sabdariffa* (HS) is one of the most widely used nutraceuticals, used traditionally to combat various illnesses due to its high flavonoid contents. The present study was aimed at evaluating the ameliorative effect of co-administration of HS and vitamin E on sub-chronic carbamazepine (CBZ)-induced alterations in semen characteristics. Thirty young male Wistar rats were divided at random into five groups containing 6 rats per groups. Group I and II were administered normal saline and carbamazepine (20 mg/kg), respectively, while group III was treated with CBZ and aqueous extract of *Hibiscus Sabdariffa* (200 mg/kg); group IV was treated with CBZ and vitamin E (VE) 30 minutes after treatment with CBZ. The regimens were administered orally by gavage once daily for a period of 8 weeks. At the end of the treatment, four animals from each group were randomly selected and sacrificed by jugular fenestration.

**Keywords:** Carbamazepine, *Hibiscus sabdariffa*, sperm count, sperm morphology, sperm motility, testicular histology, testosterone and vitamin E.

---

## I. INTRODUCTION

Carbamazepine is one of the most commonly used antiepileptic drugs. In men with epilepsy, long-term use of liver enzyme inducing antiepileptic drugs (AEDs), is associated with increased serum concentration of sex hormone-binding globulin and reduced bioactive serum testosterone, which may affect reproductive function [1]. In addition, the use of certain antiepileptic drugs may reduce sperm motility, induce sperm abnormalities and decrease testicular volume. Change in sperm quality can obviously have a direct effect on fertility in men [2][3]. *Hibiscus sabdariffa* L. is used in folk medicine against many complaints that include high blood pressure, liver diseases and fever [4][5][6][7]. In Nigeria, a decoction of the seeds is given to augment or induce lactation in poor milk let-down [8]. *Hibiscus sabdariffa* L. is taken as a common local drink, popularly known as “zobo” in Nigeria. It is cultivated for leaf, fleshy calyx, seed or fibre according to the respective properties of the two major varieties variety. ruber (red) and variety intermedium (green) [4]. The thick red and fleshy cup-shapes calyces of the flower are consumed worldwide as a cold beverage and as a hot drink (sour tea) [9]. It is known as roselle or red sorrel (English), *karkade* (Arabic), *yakuwa* (Hausa), *amukan* (Yoruba) and *okworo ozo* (Ibo). *Hibiscus sabdariffa* Linn is a herb belonging to the Malvaceae family and it is grown in Central and West Africa, South- East Asia, and elsewhere in parts of West Indies, Jamaica and Central America. In Africa, roselle is frequently cooked as a side dish, eaten with pulverized peanuts. For stewing as sauce or filling for tarts or pies, the products were indistinguishable from cranberry sauce in taste and appearance [9][10]. *Hibiscus sabdariffa* L. is an important source of

vitamins, minerals, and bioactive compounds, such as organic acids, phytosterols, and polyphenols, some of them with antioxidant properties. The phenolic content in the plant consists mainly of anthocyanins like delphinidin-3-glucoside, sambubioside, and cyanidin-3- sambubioside; other flavonoids like gossypetin, hibiscetin, and their respective glycosides; protocatechuic acid, eugenol, and sterols like -sitoesterol and ergoesterol [11]. *Hibiscus sabdariffa L.* is used as a source of food and beverages in local communities in Africa and other parts of the world. *Hibiscus sabdariffa L.* is reported to have antioxidant effect on some haematological indices and in alleviating the toxicity induced by chronic administration of sodium nitrate in Wistar rats [12]. In India, Africa and Mexico, roselle plants are valued in native medicine. Infusions of the leaves or calyces are regarded as diuretic, cholerectic, febrifugal and hypotensive, decreasing the viscosity of the blood and stimulating intestinal peristalsis. Pharmacognosists in Senegal recommend roselle extract for lowering blood pressure. Sharaf (1962) [13], confirmed the hypotensive activity of the calyces and found them antispasmodic, anthelmintic and antibacterial as well. In 1964, the aqueous extract was found effective against *Ascaris gallinarum* in poultry [9]. Sharaf (1962) [13] showed that both the aqueous extract and the colouring matter of the calyces are lethal to *Mycobacterium tuberculosis* [9]. In experiments with domestic fowl, roselle extract decreased the rate of absorption of alcohol and so lessened its effect on the system [9]. In Guatemala, roselle "ade" is a favorite remedy for the after-effects of drunkenness. The heated leaves are applied to cracks in the feet and on boils and ulcers to speed maturation of new cells. A lotion made from the leaves is used on sores and wounds [14]. The brownish-yellow seed oil is claimed to heal sores on camels. In India, a decoction of the seeds is given to relieve dysuria, strangury and mild cases of dyspepsia and debility [9]. Vitamin E can protect critical cellular structures against damage both from free radicals such as peroxy radical, hydroxyl radical, and superoxide, and from oxidation products such as malondialdehyde (MDA) and hydroxynonenal [15]. Vitamin E, as an important antioxidant, playing a role in inhibition of mutagen formation and repair of membranes and DNA. Therefore, it has been suggested that vitamin E may be useful in cancer prevention [16]. Vitamin E supplementation in cancer patients showed that vitamin E has an important neuroprotective effect [17]. Vitamin E has the ability to protect neuronal tissue in several neurodegenerative disorders, including Alzheimer's disease [18]. Oxidative stress is thought to contribute to the development of a wide range of diseases, including Alzheimer's disease [19][20], Parkinson's disease [21], diabetes [22][23], rheumatoid arthritis [24] and neurodegeneration in motor neurone diseases [25]. In many of these cases, it is unclear if oxidants trigger the disease, or if they are produced as a secondary consequence of the disease and from general tissue damage. One case in which this link is particularly well-understood is the role of oxidative stress in cardiovascular disease. Here, low-density lipoprotein (LDL) oxidation appears to trigger the process of atherogenesis, which results in atherosclerosis, and finally cardiovascular disease [26].

## II. MATERIALS AND METHODS

### 1.1 Experimental Design And Treatment Of Animals

#### 1.1.1 Acute toxicity studies of *Hibiscus sabdariffa*

Acute toxicity (LD50) of *Hibiscus sabdariffa l.* was determined using the method of Lorke [27]. The study of *Hibiscus sabdariffa l.* on Wistar rat toxicity was divided into two phases. Nine Wistar rats were used in the first phase in 3 divided groups of 3 each named group A, B and C. Group A received extract doses of 10 mg/kg body weight orally, while group B and C received extract doses of 100 and 1000 mg/kg body weight by oral route respectively. The treatment animals were observed for 24 hours for sign of discomfort or death. In the second phase, four Wistar rats were divided into four groups, named group D, E, F and G. Group D received the extract at a dose of 600 mg/kg body weight orally, group E, F and G received the extract at a dose of 1000, 1600 and 2900 mg/kg body weight, respectively. The animals were also observed for 24 hours for sign of discomfort or death. No sign of discomfort or death was observed during the period of observation. Therefore, the extract was considered relatively non-toxic even at doses higher than 5000 mg/kg [27].

#### 1.1.2 Experimental animals

Thirty adult male Wistar rats between the ages of 8-12 weeks, weighing from 120-180 g were used for this research. The animals were obtained from the Department of Pharmacology and Therapeutics, Ahmadu Bello University, Zaria. The rats were housed in the animal house of the Department of Human Physiology, Faculty of Medicine, Ahmadu Bello University Zaria, Nigeria. The animals were kept in cages under normal environmental temperature (20 – 22 °C) and fed with standard pellet diet and water given *ad libitum*.

### 1.1.3 Identification of plant and extract preparation

The *Hibiscus sabdariffa l.* plant was authenticated and given herbarium/voucher number 1056. The calyces were then shaded-dried and pounded into powder using pestle and mortar and extraction was done using the method of cold maceration [28]. Five hundred gram (500 g) of the powder was poured into a conical flask and one litre of distilled water was added to it and was shaken for 1 hour, and then allowed to stand overnight. It was then filtered using a filter paper and the filtrate was poured into an evaporating dish, and concentrated with water bath (70-75 °C) to granules. The granules/extract was then scrape off and preserved in a sample bottle.

## 1.2 Experimental procedure

A total of 30 Wistar rats were used for the experiment. They were divided into five groups of six animals each. Group I served as control and given 5 ml/kg of 0.9% saline, while groups II, III, IV and V were treated with 20 mg/kg of carbamazepine, carbamazepine (20 mg/kg) + 200 mg/kg/day of *H. sabdariffa* 30 minutes after administration of carbamazepine, carbamazepine (20 mg/kg) + vitamin E (50 IU/kg body weight) 30 minutes after administration of carbamazepine and carbamazepine (20 mg/kg) + *H. sabdariffa* (20 mg/kg) + vitamin E (50 IU/kg body weight) orally for 8 weeks, respectively. After 24 hours from the last treatment, the animals were used for the experiment. Each rat was sacrificed by jugular fenestration. After fenestration the rat was dissected and the epididymis was exposed by scrotal incisions and transferred into petri dish. The weight of the epididymis was recorded for each rat.

## 1.3 Sperm analysis

The epididymis was crushed using a blunt forceps in a petri dish and 1 ml of physiological saline solution (PSS) at room temperature (22 °C) was added to semen and mixed thoroughly using a syringe to draw and release the mixture continuously. One millilitre of 0.5% formolsaline was added to the homogenate and mixed in the petridish [29]. The semen mixture was then sucked into a red blood cell pipette to the 0.5 mark, then normal saline was sucked up to the 101 mark and allowed to settle down for about 10 minutes before introducing into haemocytometer. The normal saline in the stem of the pipette was discarded and the content of the bulb of the pipette was mixed thoroughly. A drop of the mixture was placed on the counting chamber which then spreads under the cover slip by capillary action. The counting chamber was then mounted on the slide stage of the microscope and viewed under x 40 magnification. A grid system divides the counting chamber into five major squares each containing 16 smaller boxes. The count included all the sperm cells within the five major squares using the top and right or left and bottom system of counting as described by Verma and Chinoy (2002) and Zaveneid and Polakoski (1977) [29][30].

The sperm count for a rat was calculated as =  $n \times 1 \times 10^{-6}$ /mL of semen.

## 1.4 Sperm motility

A drop of the semen mixture was placed on a glass slide using 2 ml syringe, the preparation was placed on a microscope. Sperm motility was assessed as described by Sonmez *et al.* (2007) [31]. The motility of epididymal sperm was evaluated microscopically within 2–4 min of their isolation from the caudal epididymis and data were expressed as percentages of progressive motile, non-progressive motile and non-motile spermatozoa. The percentage of motility was evaluated visually at X 40 magnification.

1. Progressive movement sperm cells
2. Non-progressive movement sperm cells
3. No movement or immotile sperm cells

## 1.5 Sperm Morphology

The epididymis was minced in 1 ml PSS to make a suspension. Sperm morphology was determined by the method of Rouge (2004). Briefly, microscope slides and nigrosin-eosin stains were pre-warmed to body temperature. A drop of stain was made onto the end of a slide and a small droplet of semen was pipette next to the stain. The edge of another slide was placed inside the drops of stain and semen, and the slide was rocked back and forth a few times to mix the sperm and

stain. A second side was smeared across the surface of the first. The second slide was dried by waving it back and forth in the air. The slide was examined using a bright field microscope using X 40 objective lens. Sperm head morphology was classified into normal and abnormal types. The abnormal spermatozoa were classified into two categories: (1) spermatozoa with defective heads (amorphous, hook less, banana shaped, double head, microcephaly and cephalo-caudal junction defects; and (2) Spermatozoa with defective tails (two-tailed, coiled/bent tails) [33].

### 1.6 Histological procedures

After the extraction of the testis from the rats, the organ was promptly and adequately treated with 10% formaldehyde (fixation) in order to preserve its structure and molecular composition. After fixation, the piece of organ was dehydrated by bathing it successfully in graded mixture of ethanol and water (70 – 100%). The ethanol was then replaced with a solvent miscible with the embedding medium. As the tissues were infiltrated with xylene, it became transparent (clearing). The impregnated tissue by xylene was placed in melted paraffin in an oven, maintained at 58 – 60°C (embedding). The heat caused the solvent to evaporate and the spaces within the tissues became filled with paraffin. The tissue together with its impregnating paraffin hardened after removal from the oven. The sections (5 µm) were then floated on water and transferred to a glass slide, and stained with haematoxylin and eosin stains. The slides were viewed under light microscope with magnification x 100.

### 1.7 Statistical analysis

The results obtained were presented as mean ± SEM. The data were analyzed using ANOVA and Tukey’s post hoc test to determine the level of significance between the control and experimental groups. Values of P < 0.05 were considered to be of statistically significance.

## III. RESULTS

The result showed that mean sperm counts in the CBZ-treated alone group was lower but higher in groups co-treated with HS, Vitamin E, and HS and vitamin E (P < 0.05) when compared to the control groups (Figure 1).

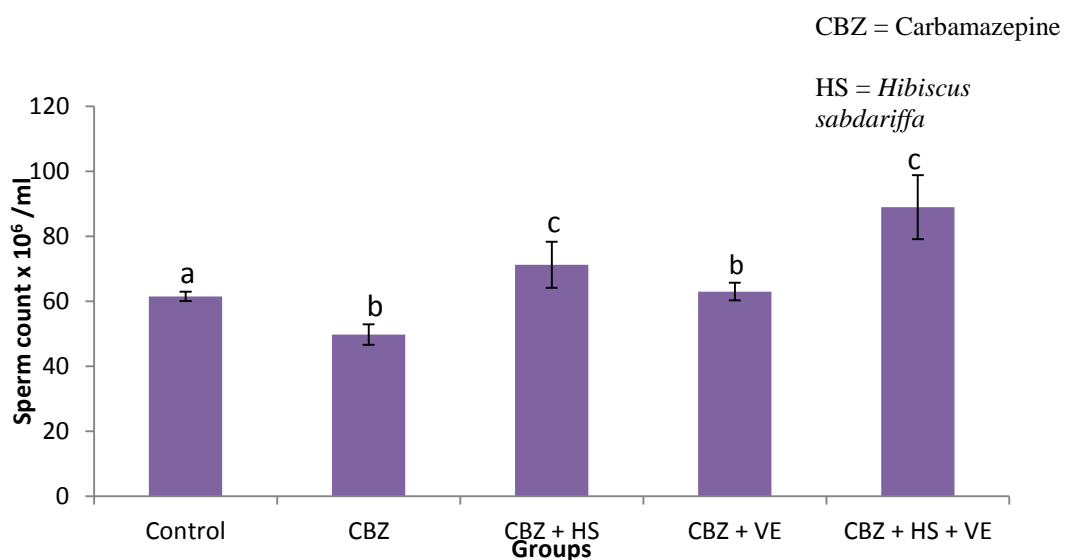
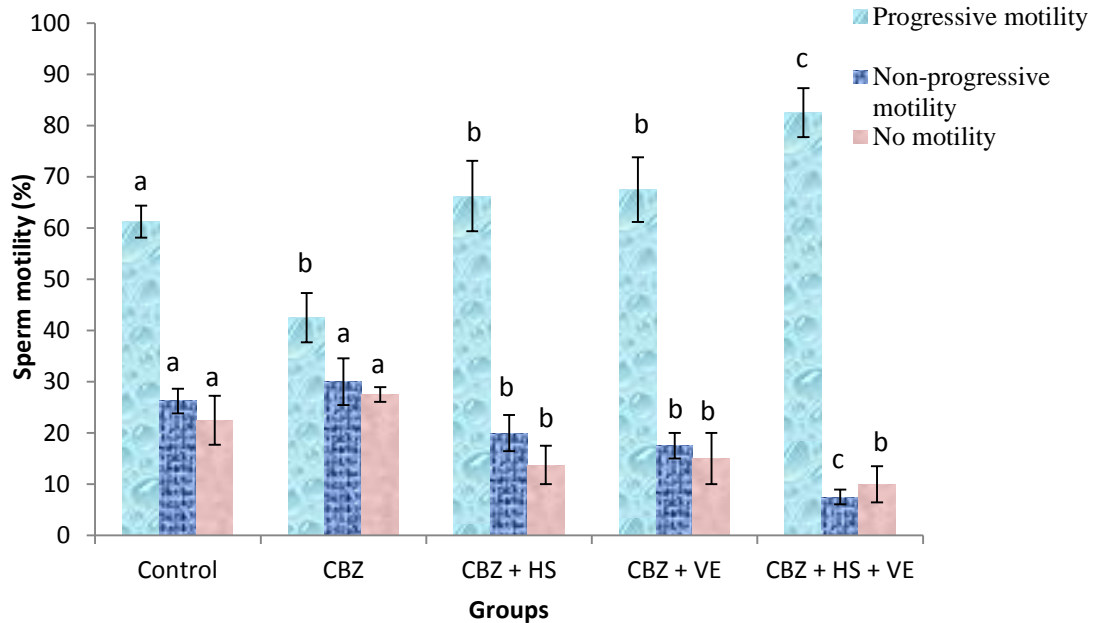


Figure 1: Effects of treatments on epididymal sperm count in adult male Wistar rats  
<sup>a, b, c</sup> = Means with different superscript letters are significantly (P < 0.05) different

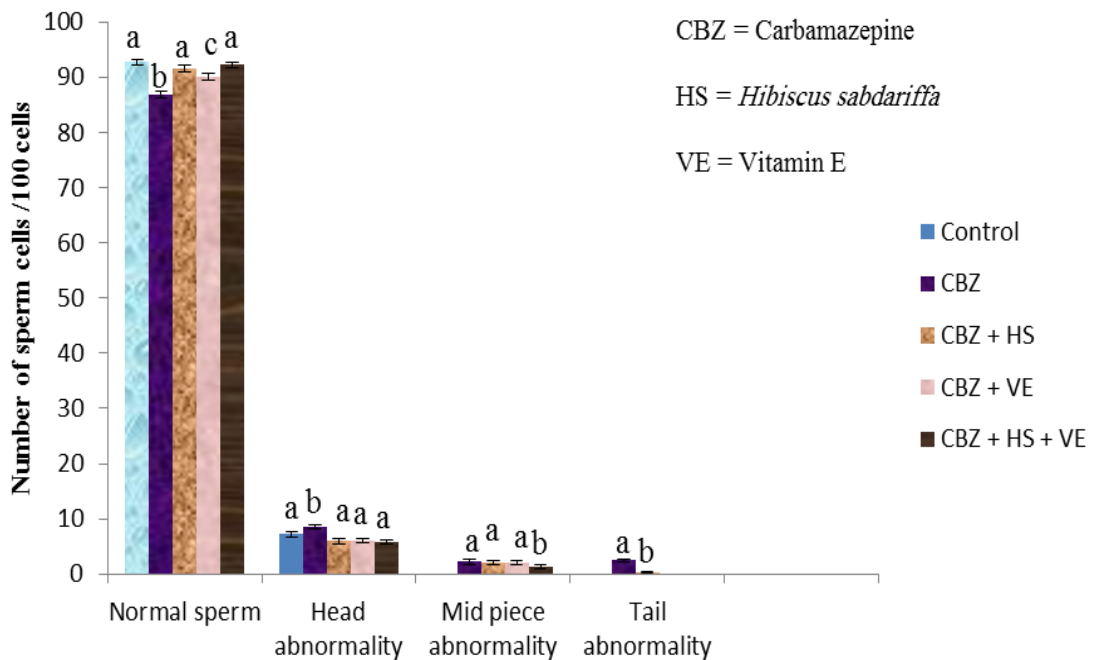
There was significant decrease in mean progressive sperm motility but an increase in the means non-progressive motility and non-motile sperm cells of the CBZ-treated group as compare to the control group (P < 0.05). While there were significant increases in mean progressive sperm motility but decrease in non-progressive motility and non-motile sperm

cell of the groups treated with CBZ in combination with HS, vitamin E, and HS and vitamin E as when compared to the CBZ-treated alone and control groups ( $P < 0.05$ ) (Figure 2).



**Figure 2: Effect of treatments on progressive sperm motility in adult male Wistar rats**  
<sup>a, b, c</sup> = Means with different superscript letters are significantly ( $P < 0.05$ ) different

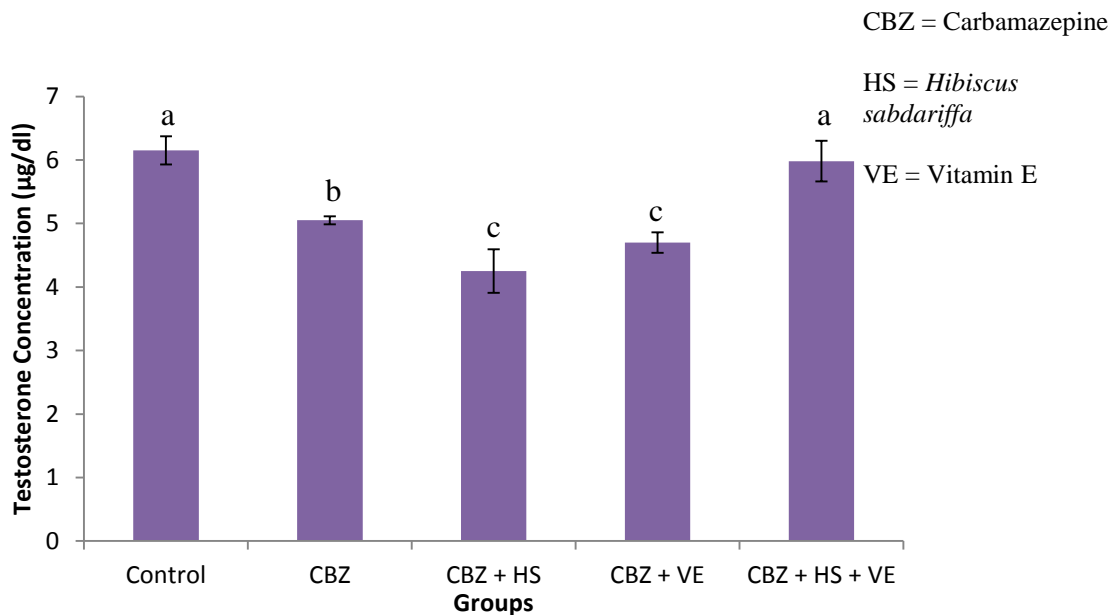
There was no considerable statistically significant different in abnormal sperm cells in the treatment groups (except for tail abnormality) ( $P < 0.05$ ) when compared to the control group (Figure 3).



**Figure 3: Effect of treatments on sperm morphology of adult male Wistar rats**  
<sup>a, b, c</sup> = Means with different superscript letters are significantly ( $P < 0.05$ ) different

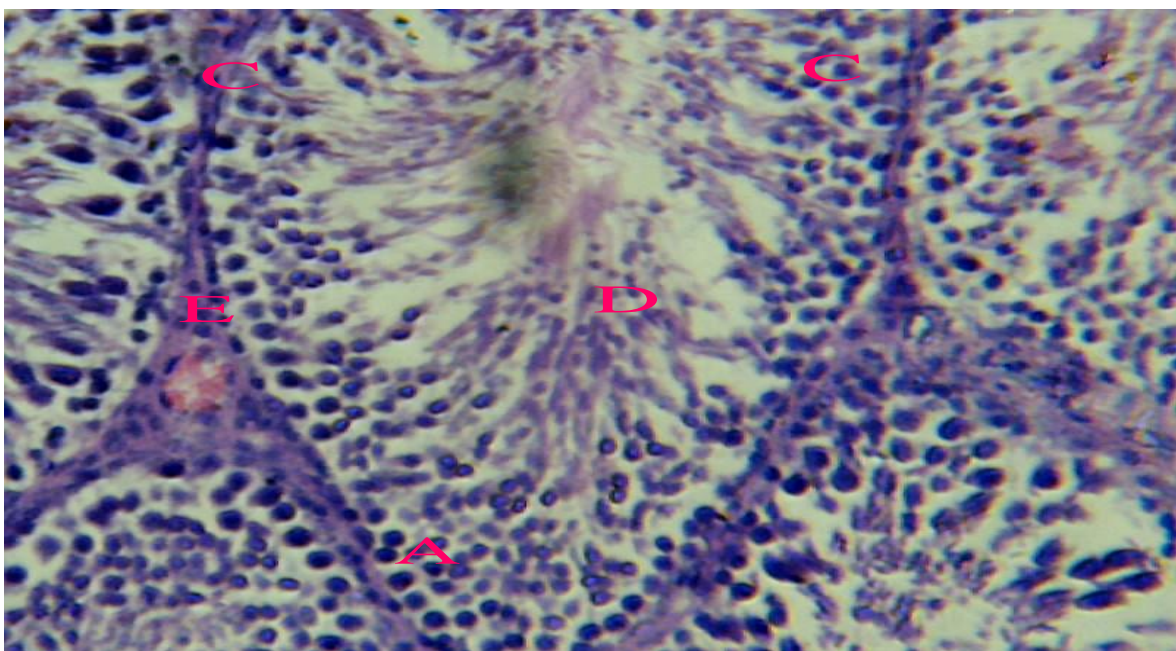


Figure 4 shows relatively decrease in mean serum testosterone level in treatment groups as compared to control group but significant increase in the group treated with CBZ in combination with HS and vitamin E only ( $P < 0.05$ ).



**Figure 4: Effects of treatments on serum testosterone concentration in adult male Wistar rats**  
 a, b, c = Means with different superscript letters are significantly ( $P < 0.05$ ) different

Plate I shows normal testicular histology of the control group treated with normal saline, plate II shows conspicuous damaged germ cell and mature spermatozoa layers of the group treated with CBZ alone, while plates III, IV and V show amelioration of damaged testes in groups treated with CBZ in combinations with HS, VE and HS + VE, respectively.



**Plate I: Photomicrograph of the testis of an adult male Wistar rat treated with normal saline. Note the normal spermatogonia layer (A) beneath the basement membrane (B), spermatocyte layer (C), spermatozoa (D) in the central lumen and interstitial space (E). H & E X 100.**

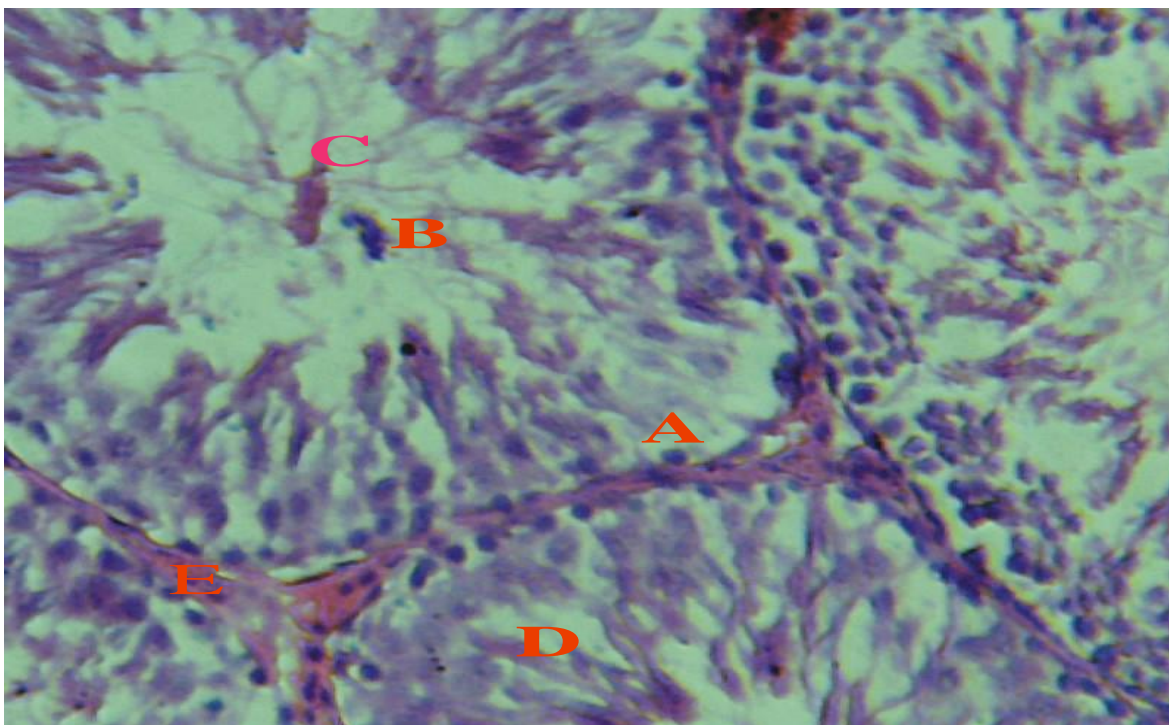


Plate II: Photomicrograph of the testis of an adult male Wistar rat treated with carbamazepine. Note the degeneration of germinal epithelia cells (A), slight vacuolation appearing between the epithelium and the spermatogenic cells and few matured spermatozoa and degenerative germ cells (B) in the central lumen (C). H & E X 100

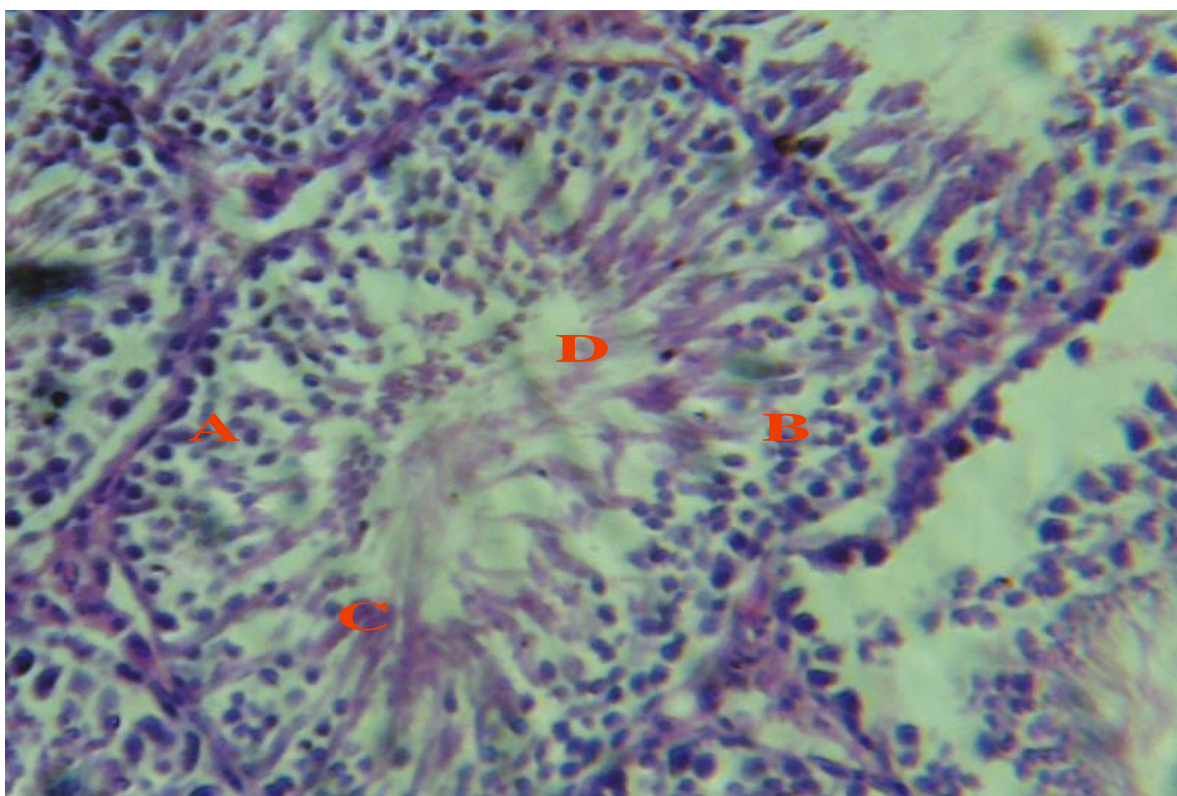


Plate III: Photomicrograph of the testis of an adult male Wistar rat treated with carbamazepine + *Hibiscus sabdariffa*. Note the scanty germ cell layer (A), spermatocytes layer (B) and spermatozoa layer (C) close to the tubular lumen (D). H & E X 100



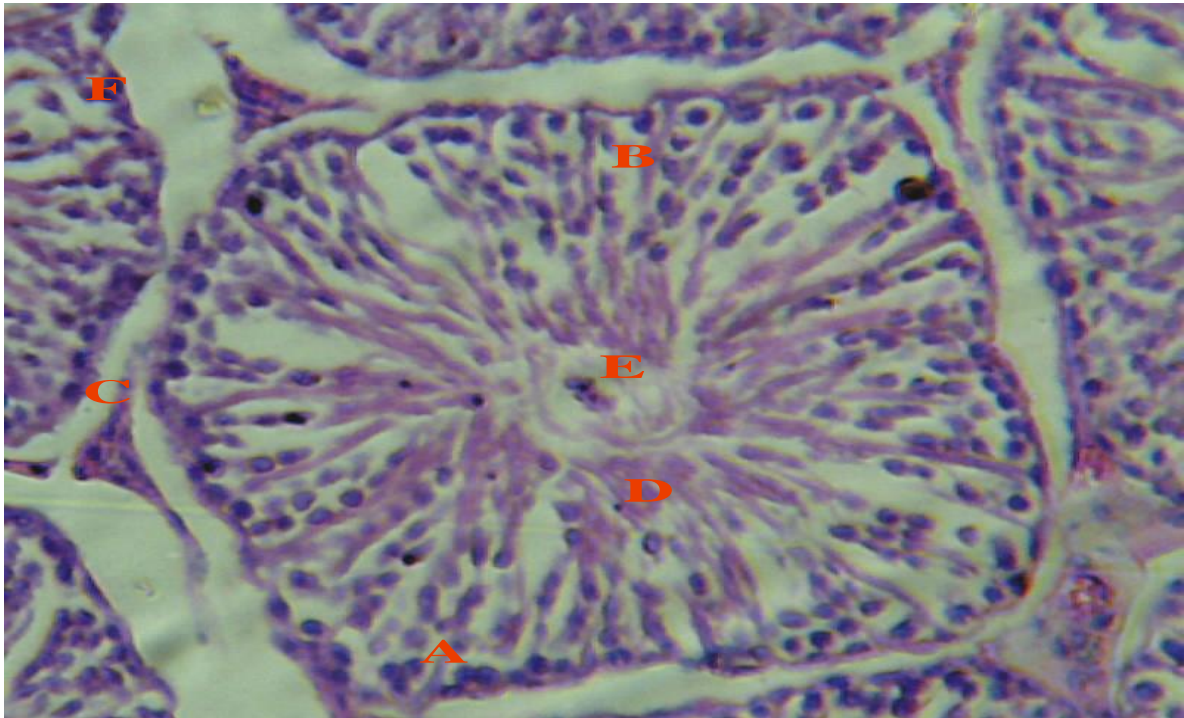


Plate V: Photomicrograph of the testis of an adult male Wistar rat treated with carbamazepine + vitamin E. Note the reduction in the number of germ cell layer (A), spermatocyte cells layer (B) and central spermatozoa layer (D) in the seminiferous tubular lumen (E) and enlargement of interstitial cell of Leydig (C) and interstitial spaces (F). H & E Mag. X 100

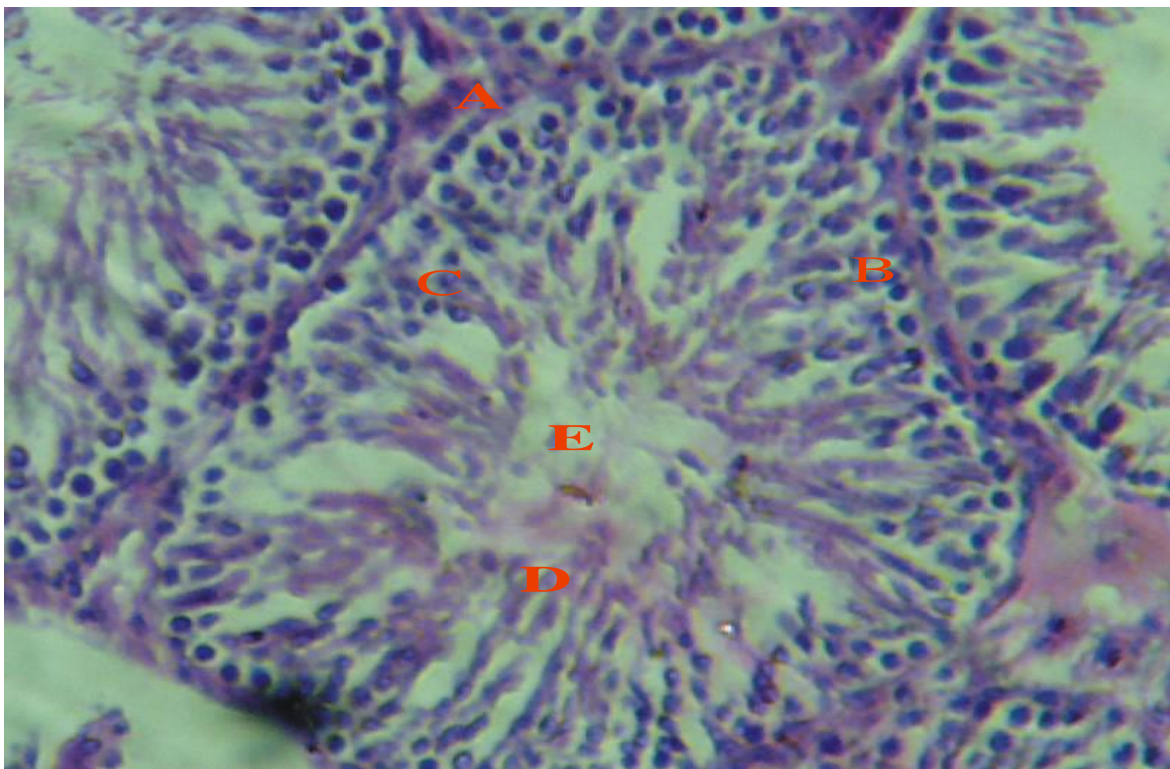


Plate VI: Photomicrograph of the testis of an adult male Wistar rat treated with carbamazepine + *Hibiscus sabdariffa* + vitamin E. Note the relatively normal spermatogonia layer (B) lining the basement membrane (A), spermatocyte layer (C), and spermatozoa layer (D) close to the center of the seminiferous tubular lumen (E). H & E X 100



#### IV. DISCUSSION

The present study showed a significant reduction in epididymal sperm concentration in the CBZ group as compared to other groups after 28 days of oral administration, which agreed with the result obtained by Leskiewicz *et al.* (2008) [34]. The lower sperm count in the CBZ group could be partly due to the induction of oxidative stress in the testes and the spermatozoa as reported by earlier workers Gallup *et al.* (2002); Isojarvi *et al.* (2004) and Krishnamoorthy *et al.* (2007) [35][3][36]. The spermatozoa are highly susceptible to damage from ROS due to high concentration of polyunsaturated fatty acids within their plasma membrane [37], high production of free radicals, resulting from mitochondrial respiration and deficient DNA repair mechanism [38]. Although, spermatozoa require a short exposure to low amount of free radicals for sperm capacitation and to become hyperactive [39], reactive oxygen species (ROS) must be continuously inactivated to a level that will not be injurious to the spermatozoa. Spermatozoa possess an array of antioxidant defence mechanisms such as superoxide dismutase (SOD), catalase (CAT) and glutathione (GPx) [40]. Anti-epileptic drugs like CBZ are capable of increasing oxidative challenge, which can be neutralized by an array of antioxidant mechanisms in the body. When the activities of antioxidant enzymes and molecules are overwhelmed, oxidative stress ensues. The resulting excess free radicals damage lipid and protein components of cell membranes. This leads to acceleration of germ cell apoptosis, resulting in a decline in sperm count and alteration of gonadal integrity and function [41].

The Sertoli cell is a major determinant of sperm output in the testes (Sharpe *et al.*, 2003) [42]. The reduced sperm count seen in this study in the CBZ group may be due to the reduced testosterone concentration possibly due to low LH and oxidative damage to the Leydig cells, consistent with the finding of Sharpe *et al.* (2003) [42]. The net effect of low testosterone levels is decreased spermatogenesis and androgen-dependent epididymal sperm maturation [43]. The present study has shown that treatment with the aqueous extract of HS and VE, ameliorated the CBZ-induced low sperm count. This may be due to anti-oxidant activities of the extract and VE apparently acting synergistically to reduce free radical load in the testes. The increase in the sperm concentration in the groups co-treated with the HS and VE may be due to decreased lipoperoxidative damage to the testicular tissues. Also, the amelioration of oxidative damage to the testes by HS and VE may have enhanced LH production, hence increasing the testosterone production by Leydig cells.

The present study showed a marked decrease in the sperm motility in the group exposed to CBZ compared to the control and other treated groups. This result agreed with previous findings by Shen and Chen (1990) [44], who reported that carbamazepine has membrane stabilizing effect and inhibit human sperm motility. The reduced sperm motility in both progressive and non-progressive movement seen in this study may be ascribed to accumulation of proteins in the testes and epididymis, secondary to androgen deprivation, resulting in increased formation of abnormal spermatozoa [45]. Sperm DNA damage occurs secondary to oxidative stress, exacerbated by a decline in local antioxidant protection, especially during epididymal maturation. This results in variety of adverse clinical outcomes [46]. Hence, a cascade of defective spermiogenic processes with characteristic retention of excess residual cytoplasmic, persistent nuclear histones, and poor zona binding and disrupt chaperone content, causing formation of dysmature cells [46].

In the current study, there was a relatively higher testosterone level in the control as compared to the treated groups. The lower serum testosterone concentration in the CBZ group may be linked to the inhibitory effect of CBZ on the secretion of pituitary gonadotropins (FSH and LH), which aid in testosterone biosynthesis [47]. Similarly, decrease in testosterone concentration seen in the CBZ-treated group may occur due to direct damage to Leydig cells [36]. Therefore, the low testosterone concentration in the CBZ-treated group as compared to the control group may be due to deleterious effect of CBZ on both the brain and the testicular tissues due to oxidative damage. The improvement seen in the groups co-treated with HS and VE suggests an ameliorative effect of HS and VE on CBZ-induced testicular and sperm defects.

Histological examination of the testes of rats treated with CBZ revealed degeneration in spermatogonia cells, lining the seminiferous tubule, associated with incomplete spermatogenesis when compared with the control group treated with normal saline. The degeneration of germ cells and abnormal interstitial spaces with degeneration of Leydig cells in CBZ treated group seen in this study may due to the cytotoxic effect of CBZ. This agrees with the findings of Shetty and Naryana (2007) [48], who reported that CBZ depresses spermatogenesis, which results in the death of immature germ cells present in the seminiferous epithelium. Improvements in the histopathological pictures with preservation of testicular integrity that were observed from rats treated with CBZ + HS and CBZ + VE could be ascribed to the antioxidant effects of HS and VE. This is consistent with the findings of Dare *et al.* (2012) [49], who showed that flavonoids, which are part

of the phytochemical constituents of HS, exhibit a wide range of biological activities, especially their ability to scavenge for hydroxyl and superoxide anion radicals. The CBZ + HS + VE group had relatively normal seminiferous tubule and germ cells, when compared to the CBZ, CBZ + HS and CBZ + VE treated groups. This result suggests better ameliorative effect of HS + VE as compared with co-treated HS or VE alone.

The present study revealed no significant difference in sperm head and mid-piece abnormalities, but a significant difference in sperm tail abnormalities in CBZ + HS, CBZ + VE and CBZ + HS + VE treated groups was recorded, compared to the control and CBZ treated groups. In the group exposed to CBZ only, relatively higher sperm morphological abnormalities were observed as compared to other treated groups. This finding agrees with the earlier report by Shetty and Naryana (2007) [48], that the abnormalities seen may be due to alterations in the process of sperm maturation, where sperm cells develop from damaged seminiferous tissue, which may have occurred as a result of the lipoperoxidative damage induced by CBZ exposure on the testicular tissues.

## V. CONCLUSION

Oral administration of carbamazepine for 8 weeks in adult male Wistar rats caused a significant decrease in sperm count, progressive sperm motility, serum testosterone concentration, and an increase in non-progressive sperm motility, non-motile sperm cells, and damage to the seminiferous tubules of the Wistar rat testis, but these effects were reversed in the groups treated with CBZ in combination with oral administration of aqueous root extract of *H. sabdariffa* and vitamin E. In conclusion, the results obtained from the present study demonstrated that CBZ treatment induced oxidative stress in the testes of Wistar rats. *Hibiscus sabdariffa* and vitamin E or their combination ameliorated carbamazepine-induced oxidative stress responses in the testes of Wistar rats. Therefore, *Hibiscus sabdariffa* has an anti-oxidant protective effect on fertility.

## REFERENCES

- [1] L. Isojarvi, E. Tauboll and A.G. Herzong, "Effect of antiepileptic drugs on reproductive endocrine function in individuals with epilepsy," *Central Nervous System Drugs*, Vol. 19, pp. 207-223, 2005.
- [2] L.S. Roste, E. Tauboll, L. Morkad, T. Bjornenak, E.R. Saetre, T. Morland and L. Gjerstad, "Antiepileptic drugs alter reproduction function in men with epilepsy," *European Journal Neurology*, Vol. 12, pp. 118-124, 2005.
- [3] J.I. Isojarvi, E. Lofgren, K.S. Jantunen, A.J. Pakarinen, M. Paivansalo, I. Rautakorpi and L. Tcomivaraara, "Effect of epilepsy and antiepileptic drugs on male reproductive health," *Neurology*, Vol. 62, pp. 247-253, 2004.
- [4] J.M. Dalziel "The Useful Plants of West Tropical Africa," The Crown Agents, London, pp. 314-315, 1973.
- [5] C.J. Wang, J.M. Wang, W.L. Lin, C.Y. Chu, F.P. Chou and T.H. Tseng, "Protective effect of Hibiscus anthocyanins against tert-butyl hydroperoxide induced hepatic toxicity in rats," *Food Chemical Toxicology*, Vol. 38, No. 5, pp. 411-416, 2000.
- [6] I.P. Odigie, R.R. Ettarh and S.A. Adigun, "The effect of aqueous extract of petals of Hibiscus sabdariffa on established stages of 2-kidney, 1-clip neurovascular hypertension," *Journal of Ethnopharmacology*, Vol. 86, No. 2-3, pp. 181-185, 2003.
- [7] B.H. Ali, N. Al-Wabel and G. Blunden, "Phytochemical, pharmacological and toxicological aspects of *H. sabdariffa* L.," a review. *Phytotherapy Reserch*, Vol. 19, No. 5, pp. 369-375, 2005.
- [8] M.A.M. Okasha, M.S. Abubakar and I.G. Bako, "Study of the effect aqueous Hibiscus sabdariffa L. seed extract on serum prolactin level in lactating albino rats," *European Journal of Science Research*, Vol. 22, No. 4, pp. 575-583, 2008.
- [9] R.J. Morton, "Roselle". In *fruit of warm climate*, C.F. Dowling, Media, Inc. Greensboro, NCP, pp. 281-286, 1987.
- [10] M.T. Olaleye, "Cytotoxicity and antibacterial activity of methanolic extract of Hibiscus sabdariffa L.," *Journal Medicinal Plants Reserch*, Vol. 1, No. 1, pp. 9-13, 2007.
- [11] H. Ali-Bradeldin, N. Al-Wabel and B. Gerald, "Phytochemical, pharmacological and toxicological aspects of Hibiscus sabdariffa L.," A review of *Phytotherapy Research*, Vol. 19, pp. 369-375, 2005.

- [12] I.G. Bako, M.A. Mabrouk and A. Abubakar, "Antioxidant effect of ethanolic extract of *H.sabdariffa* Linn in alleviating the toxicity induced by chronic administration of sodium nitrate on some haematological parameters in Wistars Rats," *Advanced Journal of Food Science and Technology*, Vol. 1, No. 1, pp. 39-42, 2009.
- [13] Sharaf, "The pharmacological characteristics of *Hibiscus sabdariffa*," *Planta Medicine*, Vol. 10, pp. 48–52, 1962.
- [14] P.F. Builders, B. Kabele-Toge, M. Builders, B.A. Chindo, A.A., Patricia and C.I. Yetunde "Wound healing potential of formulated extract from *Hibiscus sabdariffa* calyx," *Indian Journal of Pharmaceutical Science*, Vol. 75, No. 1, pp. 45–52, 2013.
- [15] A.N. Erin, M.M. Spirin, L.V. Tabidze and V.E. Kagan, "Formation of alpha-tocopherol complexes with fatty acids, A hypothetical mechanism of stabilization of biomembranes by vitamin E," *Biochemica and Biophysica Acta*, Vol. 774, pp. 96–97, 1984.
- [16] R.S. London, L. Murphy and K.E. Kitlowski, "Breast cancer prevention by supplemental vitamin E," *Journal American College Nutrition*, Vol. 4, pp. 559, 1985.
- [17] Pace, A. Savarese, M. Picardo, V. Maresca, U. Pacetti and G. Del Monte "Neuroprotective effect of vitamin E supplementation in patients treated with cisplatin chemotherapy," *Journal Clinical Oncology*, Vol. 21, pp. 927-931, 2003.
- [18] M. Sano, C. Ernesto, R.G. Thomas, M.R. Klauber, K. Schafer and M. Grundman, M, "A controlled trial of selegiline, alpha-tocopherol, or both as treatment for Alzheimer's disease," *The Alzheimer's Disease Cooperative Study*, *New England Journal of Medicine*, Vol. 336, 1216-1222, 1997.
- [19] Y. Christen, "Oxidative stress and Alzheimer's disease," *American Journal of Clinical Nutrition*, Vol. 71, No. 2, pp. 621–629, 2000.
- [20] Nunomura, R. Castellani, X. Zhu, P. Moreira, G. Perry and M. Smith, "Involvement of oxidative stress in Alzheimer disease," *Journal of Neuropathology and Experimental Neurology*, Vol. 65, No. 7, pp. 631–41, 2006.
- [21] Wood-Kaczmar, S. Gandhi and N. Wood, "Understanding the molecular causes of Parkinson's disease. Trends?," *Molecular Medicine*, 12(11): 521–8, 2006.
- [22] D. Giugliano, A. Ceriellon and G. Paolisso, "Oxidative stress and diabetic vascular complications," *Diabetes Care*, Vol. 19, No. 3, pp. 257–67, 1996.
- [23] G. Davì, A. Falco and C. Patrono, "Lipid peroxidation in diabetes mellitus," *Antioxidant Redox Signal*, Vol. 7, No. 1–2, pp. 256–68, 2005.
- [24] Hitchon and H. El-Gabalawy, "Oxidation in rheumatoid arthritis," *Arthritis Research and Therapy*, Vol. 6, No. 6, pp. 265–278, 2004.
- [25] M. Cookson and P. Shaw, "Oxidative stress and motor neurone disease," *Brain Pathology*, Vol. 9, No. 1, pp. 165–86, 1999.
- [26] L. Van Gaal, I. Mertens and C. De Block, "Mechanisms linking obesity with cardiovascular disease," *Nature*, Vol. 444, No. 7121, pp. 875–80, 2006.
- [27] Lorke, "A new approach to acute toxicity testing: archives of toxicology," *Journal of Toxicology* Vol. 54, No. 4, pp. 275-287, 1983.
- [28] G. E. Trease and W. C. Evans, *Drugs of Biological Origin, Pharmacognosy* 12th ed. United Kingdom: BalliereTindall, pp. 309-540, 1983.
- [29] R. J. Verma and N. J. Chinoy, "Effect of carica papaya seeds extract on male albino rats," *Asian Journal of Andrology*, Vol. 4, No. 1, pp. 77-78, 2002.
- [30] L. D. J. Zaveneld, K. L. Polakoski, "Collection and the physical examination of the ejaculation," *Techniques of Human Andrology*, Hafez ESE, Holland: Biomedical Press, Amsterdam, 1977, 147-156.



- [31] M. Sonmez, A. Yuce and G. Turk, "The protective effects of melatonin and Vitamin E on antioxidant enzyme activities and epididymal sperm characteristics of homocysteine treated male rats," *Reproductive Toxicology*, Vol. 23, pp. 226–231, 2007.
- [32] M. Rouge, "Sperm morphology," *Hypertexts for biomedical sciences*. Colorado: Colorado State University Press, 33-36, 2004.
- [33] P. Vijay, B. Laxminarayana and R. Yeshwanth, "Reproductive toxicity of sodium valproate in male rats," *Indian Journal Pharmacology*, Vol. 42, No. 2, pp. 90–94, 2010.
- [34] M. Leskiewicz, B. Budziszewska and W. Lasoń. "Endocrine effects of antiepileptic drugs," *Przegl Lek*, Vol. 65, No. 11, pp. 795-798, 2008.
- [35] G.G. Gallup, R.L. Burch and S.M. Platek, "Does semen have antidepressant properties?," *Archives of Sexual Behaviour*, Vol. 31, No. 3, pp. 289–93, 2002.
- [36] S.U Olive and S.M Miraglia, "Carbamazepine damage to rat spermatogenesis in different sexual developmental phase," *International Journal Andrology*, Vol. 32, pp. 563-574, 2009.
- [37] G. Krishnamoorthy, P. Venkataraman, A. Arunkumar, R.C. Vignesh, M.M Aruldas, and J. Arunakarar, "Ameliorative effect of vitamins ( $\alpha$ - tocopherol and ascorbic acid) on PCB (Aroclor 1254)- induced oxidative stress in rats epididymal sperm," *Reproductive Toxicology*, Vol. 23, pp. 239-254, 2007.
- [38] Zini, E. de Lamirande and C. Gagnon, "Reactive oxygen species in semen of infertile patients: levels of superoxide dismutase- and catalase-like activities in seminal plasma and spermatozoa," *International Journal of Andrology*, Vol. 16, pp. 183–18, 1993.
- [39] Mariana, M.J.T. De alaniz and C.A. Mara, "The impact of simultaneous intoxication with agro chemicals on the antioxidant defense system in the rats," *Pesticide Biochemistry and Physiology*, Vol. 94, pp. 93-99, 2009.
- [40] J.G. Alvarez and B.T. Storey, "Role of glutathione peroxidase in protecting mammalian spermatozoa from loss of motility caused by spontaneous lipid peroxidation," *Gamete Research*, Vol. 23, pp. 77-90, 1989.
- [41] Agarwal, R.A. Saleh and M.A. Bedaiwy, "Role of reactive oxygen species in the pathophysiology of human reproduction," *Fertility and Sterility*, Vol. 79, pp. 829-843, 2003.
- [42] R.M. Sharpe, C. McKinnell, C. Kivlin and J.S. Fisher, "Proliferation and functional maturation of Sertoli cells, and their relevance to disorders of testis function in adulthood," *Reproduction* Vol. 125, pp. 769–784, 2003.
- [43] A.J. Shetty, K. Narayana, K.L. Bairy, P. Bhat and U. D'Souza, "The effect of carbamazepine on sperm counts in Wistar rats- reflecting upon its mitogenic potential," *Reproductive Biology*, Vol. 7, No. 2, pp. 177-81, 2007.
- [44] M.R. Shen and S.S Chen, "The inhibitory effect of anticonvulsants on human sperm motility: measure with a trans-membrane migration method," *Gaoxiong Yi Xue Ke Za Zhi Journal*, Vol. 6, No. 6, pp. 295-301, 1990.
- [45] M.V. Rao and N.J. Chinoy, "Effect of estradiol benzoate on reproductive organs and fertility in the male rat," *European Journal of Obstetrics and Gynecology and Reproductive Biology*, Vol. 15, No. 3, pp. 189-198, 1983.
- [46] R.J. Aitken and G.N. De Iulius, "On the possible origins of DNA damage in human spermatozoa," *Basic Science and Reproductive Medicine*, Vol. 199, No. 2-3, pp. 219-230, 2004.
- [47] S.C. Joshi, R. Mathur and R. Gulati. "Testicular toxicity of chlorpyrifos (an organophosphate pesticide) in albino rat," *Toxicology Industrial Health*, Vol. 23, No. 7, pp. 439-444, 2007.
- [48] A.J. Shetty and K. Naryana, "The effects of carbamazepine on sperm morphology in Wistar rats," *Indian Journal of Pharmacology*, Vol. 1, No. 3, pp. 255-60, 2007.
- [49] B.J. Dare, R.O. Chukwu, A.O. Oyewopo, V.O. Makanjuola, P.O. Olayinka, I.D. Akinrinade, T.O. Olaniyan, O.D. Omotoso, M.O. Shafe, O.M. Ogundele, O.O. Beremako and M.N. Adeh, "Histological integrity of the testis of adult Wistar rats (*Rattus norvegicus*) treated with *Garcinia kola*," *Reproductive System and Sexual Disorders*, Vol. 1, pp. 1-4, 2012.